

# Novel Extracorporeal Magnetotransduction Therapy with Magnetolith<sup>®</sup> and Focused Electromagnetic Extracorporeal Shockwave Therapy in Medial Meniscal Tear – A Case Report

Karsten Knobloch<sup>1</sup>

## Abstract

The case report describes a non-invasive combination of novel extracorporeal magnetotransduction therapy (EMTT) with focused extracorporeal shockwave therapy for symptomatic medial meniscal tear in a 41-year-old gentleman. Ultra-high-frequency 33 MHz ultrasound revealed a complex medial meniscal tear with a ganglion confirmed by subsequent magnetic resonance imaging. Non-invasive treatment with combined novel Magnetolith<sup>®</sup> EMTT with focused electromagnetic extracorporeal shockwave therapy for three sessions on a weekly interval. Shear wave elastography at 6 months demonstrated comparable stiffness of the healed and the healthy contralateral meniscus. The healing of the meniscal tear could be depicted by multiparametric ultra-high-frequency ultrasound (33 MHz) with novel stress testing and shear wave elastography.

**Keywords:** Magnetic field, Extracorporeal shockwave therapy, Extracorporeal shockwave therapy, Meniscal, Ultrasound, Pain

## Introduction

Meniscal tears are classically divided into traumatic versus degenerative tears [1]. Traumatically, torn menisci possess a higher degree of degeneration than intact menisci. A torn meniscus may, thus, lead to pain and a lower quality of life [2]. However, the aforementioned differentiation is not always as straightforward as it may seem.

As far as, diagnosis is concerned, indicative physical examination often leads to magnetic resonance imaging (MRI) in suspected meniscal tears. However, even when using a 3.0 Tesla MRI accuracy may be low for longitudinal tears in the posterior horn of the medial meniscus in anterior cruciate ligament (ACL)-injured patients [3]. For complex lesions, the sensitivity of the MRI is reported from the aforementioned group with 76.5%, specificity 88.6%, accuracy 86.5%, positive predictive value of 59.1%, and negative predictive value 94.6%. Overall, detection of medical meniscus tears by 3.0 Tesla MRI was 33.3–76.5%. The use of high-frequency ultrasound for the visualization of meniscal tears has not been reported yet.

Conservative management is the mainstay of degenerative meniscal tears with mainly

physiotherapy, while a surgical approach at best with a preservation of the meniscus is chosen in traumatic cases [4]. However, a pilot experimental study reported that extracorporeal shockwave therapy (ESWT) in a single session with 0.22 mJ/mm<sup>2</sup> energy flux density with a focused device promotes healing in the avascular area in meniscal tears in Wistar rats [5]. In the further course, ESWT effects on bone-stem/progenitor cells [6] as well as on the activation of ACL remnant cells [7] have been reported lately.

The novel Magnetolith<sup>®</sup> therapy follows the principle of extracorporeal magnetotransduction therapy (EMTT), which is a non-invasive therapeutic option. EMTT is a promising new technology of treatment based on PEMF with magnetic field strength between 10 and 80 mTesla and very fast oscillating frequencies with 100–300 kHz. EMTT is characterized by high-frequency oscillating magnetic fields with an effective transduction performance of >60 kiloTesla/second (kT/s). This is in contrast to known pulsed electromagnetic field (PEMF) therapy, where effective transduction performance is <60 kT/s with the commercially available PEMF devices.

Impulses are emitted by a high-speed generator that is released in nanoseconds and an impulse release frequency of up to 8 Hz. The very short duration of each impulse ensures full electrophysical reaction without any temperature increase in the tissue including electroporation and piezoelectric effects. For PEMF, an experimental study suggests beneficial effects such as the inhibition of the synovitis through enhancing the efferocytosis of macrophages with reduced IL-1 $\beta$  and TNF-alpha levels in medial meniscus tears, which has been reported recently [8]. In intervertebral discs, PEMF reduces inflammation mediated by NF-kappa  $\beta$  and phosphorylated p38-MAPK signaling pathways [9].

## Case Report

This case report highlights the novel clinical combination of high-energy focused electromagnetic ESWT with novel EMTT with Magnetolith<sup>®</sup> for medial meniscal tear visualized and follow-up by ultra-high-frequency ultrasound and MRI. The case is reported according to the CARE guidelines for case reports [10].

A 41-year-old runner complained of medial

<sup>1</sup>Sport Praxis Prof. Knobloch, Hannover, Germany.

## Address of Correspondence

Prof. Dr. Karsten Knobloch,  
Heiligerstr. 3, Hannover - 30159, Germany.  
E-mail: professor.knobloch@sportpraxis-knobloch.de

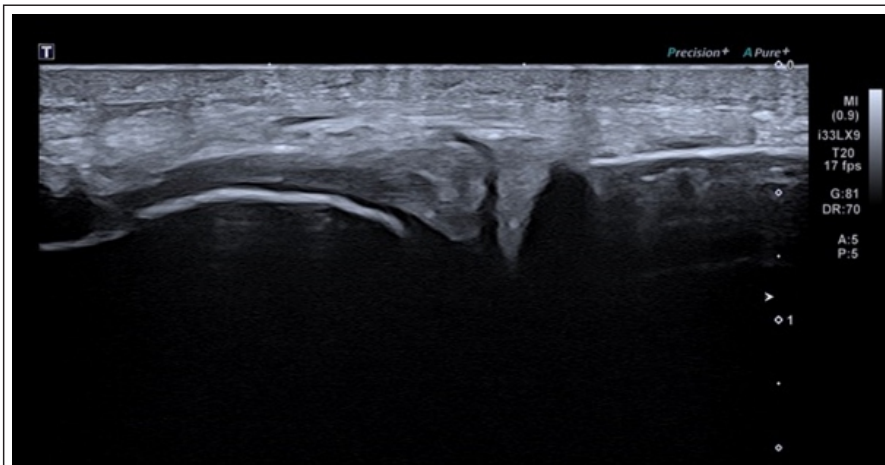


Prof. Dr. Karsten Knobloch

Submitted Date: 25 Jan 2022, Review Date: 10 Feb 2022, Accepted Date: 21 Feb 2022 & Published: 31 Jul 2022

© 2022 by Journal of Regenerative Science | Available on [www.jrsonweb.com](http://www.jrsonweb.com) | DOI:10.13107/jrs.2022.v02.i01.027

This is an open access journal, and articles are distributed under the terms of the Creative Commons Attribution-NonCommercial-ShareAlike 4.0 License (<https://creativecommons.org/licenses/by-nc-sa/4.0/>), which allows others to remix, tweak, and build upon the work non-commercially, as long as appropriate credit is given and the new creations are licensed under the identical terms.



**Figure 1:** 33MHz ultra high-frequency linear probe ultrasound (Canon Aplio i800) of the torn medial meniscus.

knee pain without a prior traumatic event. In physical examination, locking pain could be provoked on the medial knee joint space.

### Diagnostic assessment

Ultra-high-frequency 33MHz ultrasound (Canon Aplio i800, Japan) revealed a complex medial meniscal tear with a ganglion formation (Fig. 1). Subsequent 3.0 Tesla MRI confirmed the complex medial meniscal tear and the ganglion formation (Fig. 2a-d).

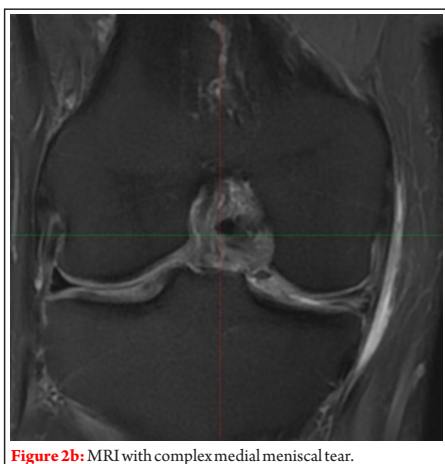
### Therapeutic intervention

A conservative approach was chosen with the unique combination of non-invasive novel Magnetolith® (EMTT, 8Hz, 6000 shots, energy level 8/8, Storz Medical, Tägerwil, Switzerland) with focused electromagnetic ESWT (0.25 mJ/mm<sup>2</sup>, 4000 shots, 4Hz, Storz Medical, Tägerwil, Switzerland) for three sessions on a weekly interval. Physiotherapy with strengthening of the thigh and proprioceptive work was initiated. No complications of either ESWT or EMTT treatment were evident, and there was no

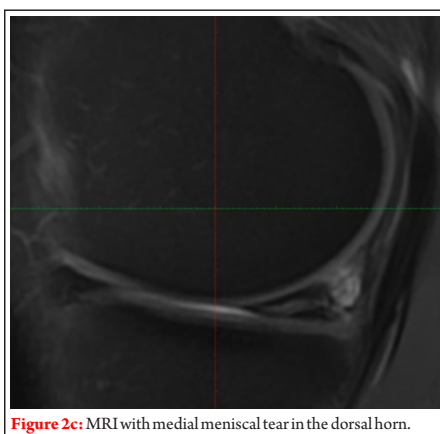
bleeding or hematoma.

### Outcomes

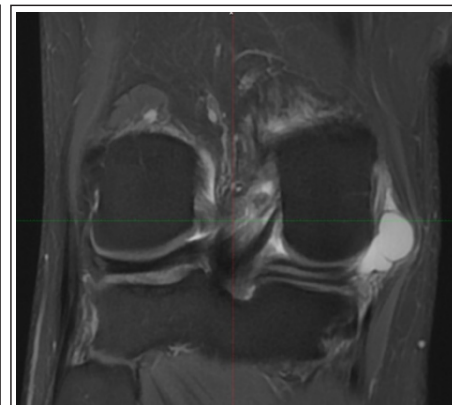
Ultra-high-frequency ultrasound stress testing at 3 and 6 months revealed a stable scar within the medial meniscal tear without clinical signs of locking. (Fig. 3). Stress testing under ultra-high-frequency ultrasound revealed a resolution of the tear at 3 and 6 months with no locking and a favorable appearance in ultrasonic stress testing with knee flexion and extension (Video 1). Shear wave elastography of the medial meniscus affected ( $2.91 \pm 0.18$  m/s) versus the healthy (revealed  $3.64 \pm 0.3$  m/s) comparable elasticity of both menisci (Fig. 4a and b). The higher the values in shear wave elastography, the higher the stiffness of the tissue examined. Depending on age and gender, a recent pilot work reported a range of 1.5–3.7 m/s corresponding to 15–36 kPa elastic modulus for a healthy medial meniscus in 17 males aged 24–30 years [11]. Clinically, running mileage could be increased to  $3 \times 7$  miles/week without any pain at 6 months.



**Figure 2b:** MRI with complex medial meniscal tear.



**Figure 2c:** MRI with medial meniscal tear in the dorsal horn.



**Figure 2a:** MRI with medial meniscal tear and ganglion formation.

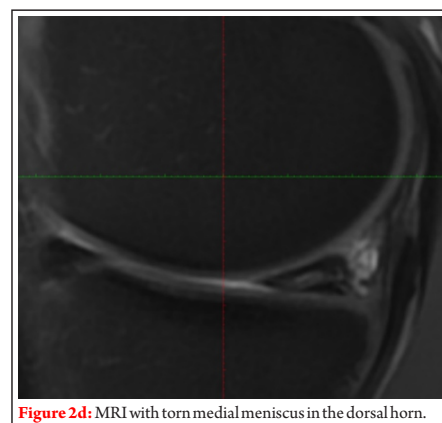
### Discussion

This is the 1st report on the non-invasive combination of focused electromagnetic ESWT and novel EMTT treatment in a medial meniscus tear. The healing of the meniscal tear could be depicted by multiparametric ultra-high-frequency ultrasound (33 MHz) over the course of 6 months with novel stress testing and shear wave elastography.

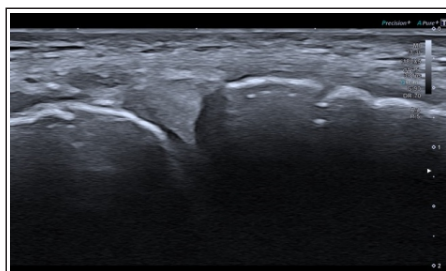
In shockwave medicine, one should differentiate focused ESWT devices from radial pressure wave devices – the latter not achieving the energy flux densities reported herein. Depending on the energy levels in focused ESWT devices, one can and should differentiate the following energy flux densities:

- Nano/very low energetic: 0.01–0.05 mJ/mm<sup>2</sup>
- Low energetic: 0.07–0.10 mJ/mm<sup>2</sup>
- Medium energetic: 0.12–0.25 mJ/mm<sup>2</sup>
- High energetic: >0.25 mJ/mm<sup>2</sup>.

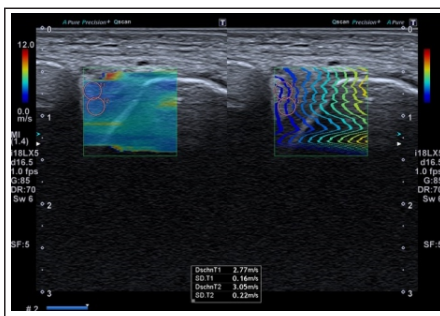
While for bone issues such as delayed unions and non-unions [12] for more than 20 years by now [13], stress fractures [14], and even osteoarthritis of the knee [15,16], a vast



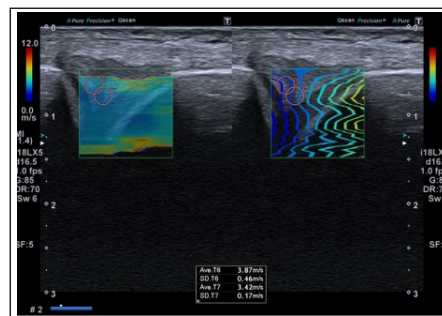
**Figure 2d:** MRI with torn medial meniscus in the dorsal horn.



**Figure 3:** Ultrasound of medial meniscus 3 months after combined ESWT and EMTT.



**Figure 4a:** Shearwave elastography at 6 months after combined ESWT/EMTT with  $2.91 \pm 0.18$  m/s of the affected side.



**Figure 4b:** Shearwave elastography at 6 months after combined ESWT/EMTT with  $3.64 \pm 0.3$  m/s of the healthy side.

number of publications reported beneficial effects of focused ESWT no such clinical paper are available on meniscus tears. In the aforementioned experimental study from Japan [5]  $0.22 \text{ mJ/mm}^2$ , so medium energetic ESWT was applied with 800 shots in Wistar rats in a single session with consecutive higher meniscus healing scores @ 4 and 8 weeks with an upregulation of CCN2, SOX9, aggrecan, and Col2A1. The effects of focused ESWT to the tissues affected say the medial meniscus and the synovia are mediated by mechanotransduction [17,18]. Mechanical stimulation of ESWT can cause a release of exosomes [19] – in myocardial tissue the release of angiogenic exosomes [20].

The novel EMTT may add clinically beneficial effects to the focused ESWT. In a randomized trial [21] on non-specific LBP comparing standard therapy (physiotherapy with core stabilization plus non-opiate analgesics) with or without additional EMTT therapy with 88 patients randomized 1:1, the combination group was superior in

terms of pain reduction on the visual analog scale and an improvement in the Oswestry disability index score. In line in rotator cuff tendinopathy, an randomized controlled trial is underpinning this observation with superior results when combining focused high-energetic ESWT and EMTT [22]. For bone stimulation, the combination of focused ESWT and novel EMTT is reported in case series for scaphoid non-unions [23], metacarpal non-unions [24], and humerus non-unions [25]. Modes of action of EMTT are electroporation and a piezoelectric effect. This pilot case highlights the potential of the combination of focused electromagnetic ESWT and novel EMTT in meniscal healing clinically. Future prospective controlled trials are warranted to elucidate its role in the field of sports medicine as well as an adjunct after surgery for more rapid rehabilitation.

The combination of novel non-invasive Magnetolith® (EMTT) with focused high-energetic ESWT for three sessions on a weekly interval can significantly improve the

healing in a medial meniscal tear. Ultra-high-frequency ultrasound stress testing may further delineate the functional status of a medial meniscal tear. To the best of my knowledge, this is the first report to apply EMTT and ESWT for medial meniscal tears which were followed-up by ultra-high-frequency ultrasound stress testing.

### Conclusion

The author has received lecture honoraria by TRB Chemedica, Canon Medical System, Storz Medical AG. None of these had or have any implications for the case report provided herein. Written informed consent was obtained from the patient for publication of this case report and accompanying images. Since this is a single case report only, no IRB approval was necessary. No funding has been received. All relevant data are within the paper and its Supporting Information files.

**Declaration of patient consent:** The authors certify that they have obtained all appropriate patient consent forms. In the form, the patient has given his consent for his images and other clinical information to be reported in the Journal. The patient understands that his name and initials will not be published, and due efforts will be made to conceal his identity, but anonymity cannot be guaranteed.

**Conflicts of Interest:** Nil. **Source of Support:** None.

## References

1. Avendaño-Coy J, Comino-Suárez N, Grande-Muñoz J, Avendaño-López C, Gómez-Soriano J. Extracorporeal shockwave therapy improves pain and function in subjects with knee osteoarthritis: A systematic review and meta-analysis of randomized clinical trials. *Int J Surg* 2020;82:64-75.
2. Bedewi MA, Elsifey AA, Saleh AK, Alfaifi T. Shear wave elastography of the knee menisci. *J Int Med Res* 2020;48:300060520976048.
3. Beutler S, Regel G, Pape HC, Machtens S, Weinberg AM, Kreimeike I, et al. Extracorporeal shock wave therapy for delayed union of long bone fractures – Preliminary results of a prospective cohort study. *Unfallchirurg* 1999;102:839-47.
4. Lu CC, Chou SH, Shen PC, Chou PH, Ho ML, Tien YC. Extracorporeal shock wave promotes activation of anterior cruciate ligament remnant cells and their paracrine regulation of bone marrow stromal cells' proliferation, migration, collagen synthesis, and differentiation. *Bone Joint Res* 2020;9:458-68.
5. d'Agostino MC, Craig K, Tibalt E, Respizzi S. Shock wave as biological therapeutic tool: From mechanical stimulation to recovery and healing, through mechanotransduction. *Int J Surg* 2015;24:147-53.
6. Gollmann-Tepeköylü C, Pölzl L, Graber M, Hirsch J, Nägele F, Lobenwein D, et al. miR-19a-3p containing exosomes improve function of ischaemic myocardium upon shock wave therapy. *Cardiovasc Res* 2020;116:1226-36.
7. Hashimoto S, Ichinose T, Ohsawa T, Koibuchi N, Chikuda H. Extracorporeal shockwave therapy accelerates the healing of a meniscal tear in the avascular region in a rat model. *Am J Sports Med* 2019;47:2937-44.
8. Hsu CC, Cheng JH, Wang CJ, Ko JY, Hsu SL, Hsu TC. Shockwave therapy combined with autologous adipose-derived mesenchymal stem cells is better than with human umbilical cord Wharton's Jelly-derived mesenchymal stem cells on knee osteoarthritis. *Int J Mol Sci*



2020;21:1217.

9. Knobloch K. Novel extracorporeal magnetotransduction therapy with Magnetolith and high-energy focused electromagnetic extracorporeal shockwave therapy as bone stimulation therapy for scaphoid nonunion – A case report. *Med Case Rep Study Protoc* 2020;2:1.

10. Knobloch K. Extracorporeal magnetotransduction therapy (EMTT) and high-energetic focused extracorporeal shockwave therapy (ESWT) as bone stimulation therapy for metacarpal non-union – A case report. *Handchir Mikrochir Plast Chir* 2021;53:82-6.

11. Knobloch K. Bone stimulation 4.0 – Combination of EMTT & EMTT in humerus nonunion. *Unfallchirurg* 2022;125:323-6.

12. Klüter T, Krath A, Stukenberg M, Gollwitzer H, Harrasser N, Knobloch K, et al. Electromagnetic transduction therapy and shockwave therapy in 86 patients with rotator cuff tendinopathy: A prospective randomized controlled trial. *Electromagn Biol Med* 2018;37:175-83.

13. Kopf S, Beaufils P, Hirschmann MT, Rotigliano N, Ollivier M, Pereira H, et al. Management of traumatic meniscus tears: The 2019 ESSKA meniscus consensus. *Knee Surg Sports Traumatol Arthrosc* 2020;28:1177-94.

14. Krath A, Klüter T, Stukenberg M, Zielhardt P, Gollwitzer H, Harrasser N, et al. Electromagnetic transduction therapy in non-specific low back pain: A prospective randomised controlled trial. *J Orthop* 2017;14:410-5.

15. Lohmander LS, Englund PM, Dahl LL, Roos EM. The long-term consequence of anterior cruciate ligament and meniscus injuries: Osteoarthritis. *Am J Sports Med* 2007;35:1756-69.

16. Moretti B, Notarnicola A, Garofalo R, Moretti L, Patella S, Marlinghaus E, et al. Shock waves in the treatment of stress fractures. *Ultrasound Med Biol* 2009;35:1042-9.

17. Ouyang J, Zhang B, Kuang L, Yang P, Du X, Qi H, et al. Pulsed

electromagnetic field inhibits synovitis via enhancing the efferocytosis of macrophages. *Biomed Res Int* 2020;2020:4307385.

18. Pözl L, Nägele F, Hirsch J, Graber M, Grimm M, Gollmann-Tepeköylü C, et al. Exosome isolation after in vitro shock wave therapy. *J Vis Exp* 2020;(163). doi: 10.3791/61508.

19. Riley DS, Barber MS, Kienle GS, Aronson JK, von Schoen-Angerer T, Tugwell P, et al. CARE guidelines for case reports: Explanation and elaboration document. *J Clin Epidemiol* 2017;89:218-35.

20. Schaden W, Mittermayr R, Haffner N, Smolen D, Gerdesmeyer L, Wang CJ. Extracorporeal shockwave therapy (ESWT) – First choice treatment of fracture non-unions? *Int J Surg* 2015;24:179-83.

21. Kim SH, Lee HJ, Jang YH, Chun KJ, Park YB. Diagnostic accuracy of magnetic resonance imaging in the detection of type and location of meniscus tears: Comparison with arthroscopic findings. *J Clin Med* 2021;10:606.

22. Tang X, Coughlin D, Ballatori A, Berg-Johansen B, Waldorff EI, Zhang N, et al. Pulsed electromagnetic fields reduce interleukin-6 expression in intervertebral disc cells via nuclear factor- $\kappa$ B and mitogen-activated protein kinase p38 pathways. *Spine (Phila Pa 1976)* 2019;44:E1290-7.

23. Wesdorp MA, Eijgenraam SM, Meuffels DE, Bierma-Zeinstra SM, Kleinrensink GJ, Bastiaansen-Jenniskens YM, et al. Traumatic meniscal tears are associated with meniscal degeneration. *Am J Sports Med* 2020;48:2345-52.

24. Willems A, van der Jagt OP, Meuffels DE. Extracorporeal shock wave treatment for delayed union and nonunion fractures: A systematic review. *J Orthop Trauma* 2019;33:97-103.

25. Zhao Z, Wang Y, Wang Q, Liang J, Hu W, Zhao S, et al. Radial extracorporeal shockwave promotes subchondral bone stem/progenitor cell self-renewal by activating YAP/TAZ and facilitates cartilage repair in vivo. *Stem Cell Res Ther* 2021;12:19.

**Conflict of Interest: NIL**  
**Source of Support: NIL**

#### How to Cite this Article

Knobloch K | Novel Extracorporeal Magnetotransduction Therapy with Magnetolith® and Focused Electromagnetic Extracorporeal Shockwave Therapy in Medial Meniscal Tear – A Case Report | *Journal of Regenerative Science* | December 2022; 2(1): 51-54.